


available at www.sciencedirect.comjournal homepage: www.elsevier.com/locate/burns

Amnion in the treatment of pediatric partial-thickness facial burns

Ludwik K. Branski¹, David N. Herndon¹, Mario M. Celis, William B. Norbury, Oscar E. Masters, Marc G. Jeschke*

Shriners Hospital for Children and University of Texas Medical Branch, 815 Market Street, Galveston, TX 77550, USA

ARTICLE INFO

Article history:

Accepted 21 June 2007

Keywords:

Amnion
Partial-thickness burns
Clinical trial
Wound healing

ABSTRACT

Background: Wound coverage for second-degree burns remains a clinical challenge. Human amniotic membranes have been used for many years in the treatment of burns; however, no large prospective clinical trials have been published. In this article, we present a novel and standardized procurement and processing method for amnion and investigate, whether the use of this biological dressing is safe and may represent a new therapeutic option for children with partial-thickness facial burns compared to standard topical treatment.

Methods: Patients with partial-thickness burns of the face, neck and head admitted between 2003 and 2005 were included in this study. They were divided into two groups to receive either amnion ($n = 53$) or topical antimicrobials ($n = 49$). Demographics (age, gender, ethnicity, TBSA, burn areas), length of hospital stay (LOS), rate of infections (RI), time to total healing, and frequency of dressing changes were compared between the two groups. The long-term outcome was assessed in nine patients in the amnion group and eight patients in the topical group, who returned for up to 12-month follow-up visits.

Results: Patients in the amnion group had significantly less dressing changes than in the control group ($p < 0.05$). Time to healing, length of stay and the development of hypertrophic scarring was not different between the groups. Use of amnion was not associated with an increased risk of local infection.

Conclusion: This study indicates that amnion is safe and has advantages as wound coverage for second-degree facial burns compared to the standard topical ointments. Further studies with the use of amniotic membranes on the trunk and the extremities, as well as for coverage of grafted third-degree burns, have yet to be performed.

© 2007 Elsevier Ltd and ISBI. All rights reserved.

1. Background

Human amniotic membrane has been used for centuries as a biological wound dressing. In China and Japan, amnion is considered a potent medication for the treatment of many diseases and believed to have “magical strength of youth” (quoted by Tyszkiewicz et al. [1]). In Western medicine,

amniotic membranes have been used since the beginning of the last century. The first reported use of amnion in burn wounds was by Sabella [2], shortly after Davis used amniotic membrane in skin transplantations in 1910 [3]. However, it soon became clear that amnion could not be used as a permanent skin transplant, but only as a temporary biological wound dressing. Advantages of amnion as a temporary

* Corresponding author. Tel.: +1 409 770 6742; fax: +1 409 770 6919.
E-mail address: majeschk@utmb.edu (M.G. Jeschke).

¹ These authors contributed equally to this work.
0305-4179/\$34.00 © 2007 Elsevier Ltd and ISBI. All rights reserved.
doi:10.1016/j.burns.2007.06.007

dressings have been reported, most notably alleviation of pain, the prevention of infection [4-7], acceleration of wound healing [3,6,8], and good handling properties [9]. The first use of amnion as a temporary skin substitute in burn wound care was reported by Douglas [10]. It was subsequently used in the treatment of partial-thickness burns [5,8,11,12].

In the last 20 years, there has been an increasing body of literature addressing the use of amnion in chronic wounds and burns. In order to make amnion a standard dressing alternative, safe and reliable production methods had to be implemented. To meet these needs, in several countries amnion banks have been established alongside tissue banks [1,13,14]. At the Shriners Hospital for Children and the University of Texas Medical Branch, we also developed a new processing method for human amniotic membranes.

Partial-thickness burns involve damage to the upper layer of skin, which leaves nerve endings exposed, and therefore represent the most painful of several categories of thermal injuries. Historically, partial-thickness burns were treated conservatively by debriding the blisters, by daily washing, and the application of new bandages with topical medications two to four times each day. These procedures cause excruciating pain and anxiety in patients even with the use of narcotics. In order to reduce pain, to provide better infection control and faster wound healing, and to minimize stress for both patient and nurse, a number of occlusive dressings have been developed in the recent years [15]. These skin substitutes allow re-epithelialization to occur underneath and eliminate the need for daily cleansing and frequent dressing changes.

At our institution, partial-thickness burns of the trunk and the extremities are now mostly treated with the use of Biobrane[®], a biosynthetic skin substitute composed of an outer silicone film, nylon fabric partially imbedded into the film, and a bovine collagen layer. Biobrane[®] shows good results both in short- and long-term clinical observations [15], but has deficits in conformability and handling. For burns of the face and neck region, it is therefore not the dressing of choice.

Amnion has the advantage of being thin, adhesive, easily moldable and removable (see Table 1). These qualities are of great importance for our predominantly pediatric population. Therefore, the use of amniotic membranes in children with partial-thickness burns seems feasible.

Table 1 – Qualities of an ideal dressing for partial-thickness burns

Dressing quality	Amniotic membrane
Pain relief	+++
Infection prevention	+++
Good adherence to wound bed	+++
Promotion of re-epithelialization	+++
Cost factor	++
Moist wound healing environment	++
Elasticity/conformability	+++
Easy application	++
Prevention of heat loss	+
Availability	++

+++, very good; ++, average; +, below average.

In this study, we performed a large safety trial in order to determine if amnion, produced according to our new protocol, would provide reduction of necessary dressing changes, shorten length of hospital stay, influence scarring, and improve long-term recovery in partial-thickness facial burns when compared to standard topical treatment.

2. Materials and methods

2.1. Procurement and preparation of amnion

We developed a safe and efficacious procedure for obtaining amnion post partum and for screening, processing and storage. All processing procedures are in accordance with our internal tissue bank guidelines and the guidelines of the American Association of Tissue Banks (AATB).

After informed consent, medical history was obtained and screening for potential risk factors such as cancer, infectious diseases, drug abuse, and sexual behavior performed. The presumptive female donors were tested for Hepatitis B and C, Rapid Plasma Reagin for Syphilis Screening, and Human Immunodeficiency Virus 1 and 2. The testing was done at the time of delivery and 60-90 days after delivery during a scheduled outpatient appointment.

In order to avoid any risk of transplanting infectious material, only amnion from cesarean sections was used in this study. Immediately after delivery, placentas with adherent fetal membranes were washed with Ringer's solution; chorion and amnion were separated by trained personnel. The tissue was then transferred to a sterile container in the delivery room, immediately transported at 4 °C to the processing site, where it was processed within 12 h of arrival.

At the tissue bank, amnion was rinsed and soaked in saline and Dakin's solution (0.25% sodium hypochlorite solution) in order to remove blood and other contaminants. It was then stored in RPMI 1640 with antibiotics (amphotericin B 50 mg/L, vancomycin 50 mg/L, ciprofloxacin 50 mg/L and trimethoprim 50 mg/L) at 4 °C for a minimum of 3 days and up to 7 days. After 1 h, a sample of the storage medium was aliquoted for microbiological testing.

The epithelial surface of the membrane was removed by treatment with 0.25% trypsin-EDTA (Sigma-Aldrich, St. Louis, MO) diluted 1:4 with phosphate buffer solution. The amnion was placed on a rotator and agitated for 24 h at room temperature. After draining off excess trypsin, the membrane was placed in Triton X-100 detergent (F. Hoffmann, La Roche, Basel, CH) diluted 1:100 with phosphate buffer solution and placed on a rotator for 24 h at room temperature. Finally, the membrane was rinsed with phosphate buffer solution.

For long-term storage, the amnion was placed in 12.5% glycerol for 20 min, cut into 250 cm² pieces, folded in fine-mesh gauze and sealed in sterile plastic pouches. The plastic pouches were placed into foil pouches, frozen in a control rate freezer and stored at -80 °C until needed.

2.2. Study design

The safety study was approved by the institutional review board of the University of Texas Medical Branch. Patients with

partial-thickness burns of the face, head and neck, and a total burn size under 40% total body surface area (TBSA), were enrolled in this study. Patients with full-thickness burns or deep partial-thickness burns of face and neck that led to subsequent skin grafting, and patients with burns over 40% TBSA or 10% TBSA full-thickness burns, were not eligible for the study. Primary outcomes were time to total healing and dressing change frequency.

At hospital admission, the depth of the incurred burns were assessed by experienced surgeons, both resident and attending staff, which was verified and corrected within the first 24–48 h after admission, if necessary. A member of the research team contacted the patient and its family about the participation in this study. Age, gender, ethnicity, area of burn, and burn etiology were obtained. Patients were randomized to receive facial amnion with antimicrobial ointment (Group 1) or facial antimicrobial ointment alone (Group 2, control). The topical antibiotic crème used in both groups consisted of 1% nystatin and 2% polymyxin B/bacitracin (Shriners Hospital for Children Pharmacy, Galveston, TX). Usually, patients stayed in the intensive care unit for no longer than 1 or 2 days and were then discharged to outside apartments with daily follow-up visits in the outpatient clinic. During their visits, the dressings were inspected by

experienced staff. Patients in group 2 received daily dressing changes, wound cleaning, and re-application of topical antibiotics; patients in group 1 only received re-application of amnion, if needed. The amniotic membranes were covered with topical antibiotic crème (Fig. 1). The tubroom nurses monitored the wound healing progress and recorded any unusual occurrences (infections, general dressing problems, allergic reactions, etc.). In most cases, patients were completely discharged within four to seven days after their discharge from the ICU. The amount of tubroom visits, facial dressing re-applications, and amniotic membranes used, was recorded for each patient.

2.3. Scar analysis

In the follow-up phase, patients returning to the outpatient clinic were examined for remaining open wounds, hypo- or hyperpigmentation, scar color, pliability and elevation. Photographs were taken at a standardized distance of approximately 90 cm from the patient. Two blinded observers then evaluated facial scars using 35 mm photographs of the patients. The total facial scarring was determined using the Hamilton Scar Scale [16]. An average value was obtained for the measurements.

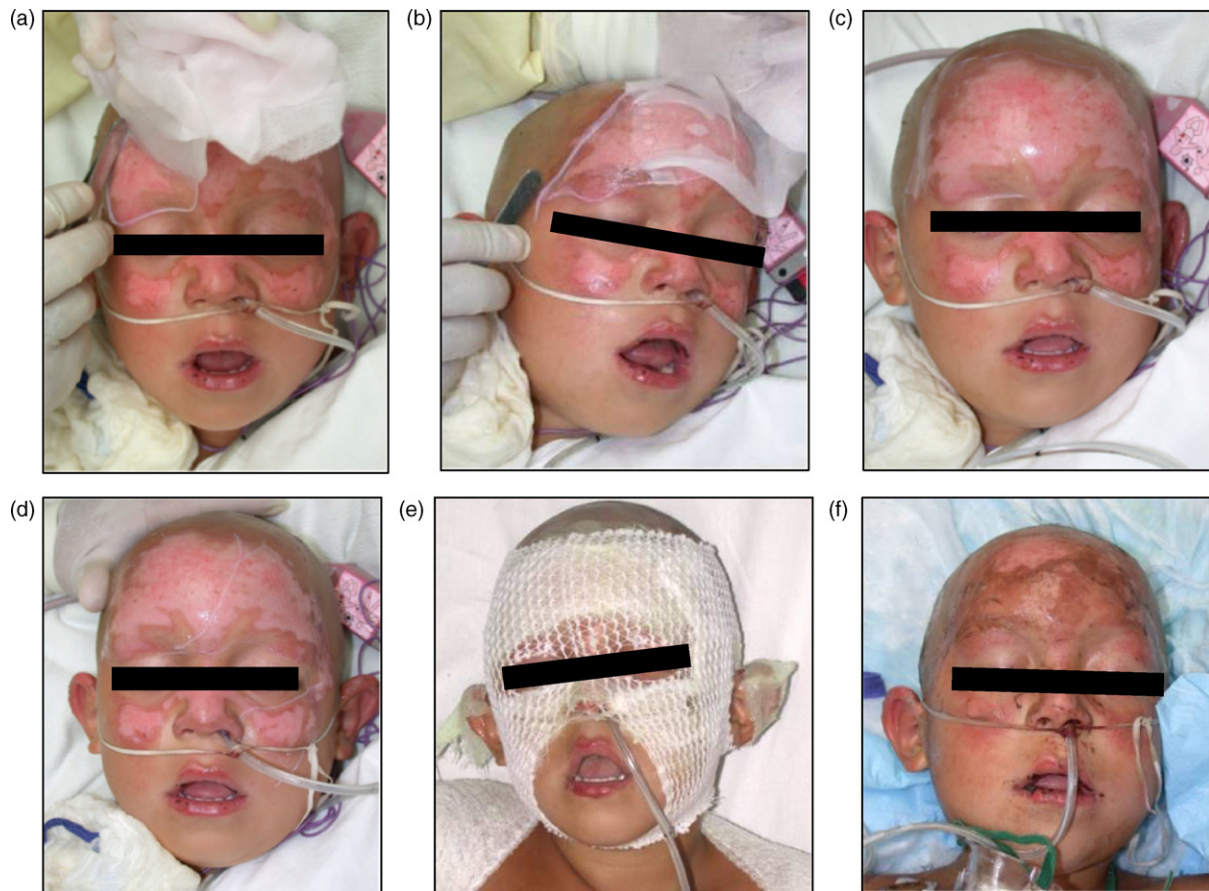

Fig. 1 – Three-year-old male patient with 3% partial-thickness burn in the face. Application of Amnion after cleaning and drying of the wound is demonstrated. (a and b) Amnion is released from the gauze and molded to the contours of the face. (c and d) Ideal adherence of amnion after application. (e) Gauze dressing with Poly/Myco ointment as coverage against removal of amnion. (f) Wound healing at 3 days post-burn.

Table 2 – Demographics

	Amnion	Control
Patients	53	49
Age (year)	7 ± 4	7 ± 4
Ethnicity		
Black (%)	21	18
Hispanic (%)	32	33
White (%)	47	49
Gender (M:F)	37: 16	35: 14
Burn type		
Scald (%)	43	45
Flame (%)	57	55
Burn to admit (day)	1 ± 1	1 ± 1
TBSA burn (%)	12 ± 7	11 ± 6
Face/head/neck (% TBSA)	4 ± 2	4 ± 2
Upper extremities (% TBSA)	4 ± 3	3 ± 3
Lower extremities (% TBSA)	3 ± 3	2 ± 3
Anterior trunk (% TBSA)	3 ± 3	2 ± 3
Posterior trunk (% TBSA)	1 ± 2	1 ± 2
Length of stay (day)	2 ± 3	2 ± 3
Inhalation injury (%)	6	4
Local infections (n)	1	2

Data presented as mean ± S.D. Local infections presented as the total number within the groups.

2.4. Statistical analysis

Student's t-test was used to examine the difference between groups in the first phase of the study. A repeated-measure ANOVA with post hoc Tukey's test was used in the assessment of scars. $p < 0.05$ was accepted as indicating significance.

3. Results

3.1. Patient demographics

A total of 120 patients entered the trial between 2003 and 2005. The age ranged from 1 to 16 years. After randomization, 59 patients were included in the control group and 61 patients in the amnion group. Subsequently, 10 patients in the control group and 8 patients in the amnion group had to be withdrawn from the study due to deep partial-thickness burn areas that made skin grafting of face, head or neck necessary; this left 53 patients in the amnion group and 49 patients in the control group. Detailed demographics are shown in Table 2. No significant differences were seen in patient age, ethnicity and the types of burns. Patients in both groups had a similar burn size; most of the patients had no full-thickness burns. In case

of a third degree burn, patients were subject to a longer stay that involved excision and grafting. These procedures did not affect the dressing changes and healing times of the facial burns, but accounted for the increase in mean length of stay to 2 ± 3 days. Only few patients per group (6 in the amnion group and 4 in the control group) were afflicted by an inhalation injury.

Local infections included the occurrence of any visible infection in the face or the neck after application of dressing or topicals. Only one patient per group showed signs of local infection; microbiology swabs were taken and patients treated with systemic antimicrobial therapy according to the results.

3.2. Acute stay and tubroom visits

The average amount of outpatient visits per patient was similar in both groups (7 ± 4 visits in the control group versus 7 ± 3 visits in the amnion group), which correlates with the similar mean length of stay and burn size. However, the amount of re-applications of facial dressings in the amnion group was significantly lower than in the control group (0.5 ± 2 versus 6 ± 3 re-applications, $p < 0.01$). Amnion had to be re-applied in approximately 10% of the cases, mostly after patients had pulled their dressing off or after insufficient coverage of the burn wound was observed. The average size of the amniotic membrane applied to the face and neck was $590 \pm 297 \text{ cm}^2$ (Table 3). Healing time in the amnion group was faster than in the control group (6 ± 2 days versus 8 ± 2 days), however this difference did not reach the 95% confidence interval.

3.3. Follow-up visits

During the follow-up visits, patients were examined and digital photographs taken (Figs. 3 and 4). From the whole group of 102 patients, 17 patients returned for a complete set of follow-up visits. Facial hypertrophic scarring was diagnosed in eight patients in the control group and nine patients in the amnion group. The results of scar assessment using the Hamilton Scar Scale did not show significantly different results between the two groups; the overall reduction in scar visibility and redness, that is expected over a period of 12 months, is reflected equally in both groups (see Fig. 2).

4. Discussion

The most important qualities of amnion include infection control, low antigenicity, antimicrobial potential, good adherence to the wound surface, and cheap production and storage.

Table 3 – Dressing changes

Dressing changes	Amnion	Control	p
Average no. of tubroom visits (in- and outpatient)	7 ± 3	7 ± 4	ns
Average no. of facial dressing re-applications	0.5 ± 2	6 ± 2	<0.05
Average time until full healing (day)	6 ± 2	8 ± 2	ns
Amnion—mean size of membrane applied (cm ²)	590 ± 297	na	na

Data presented as mean ± S.D.

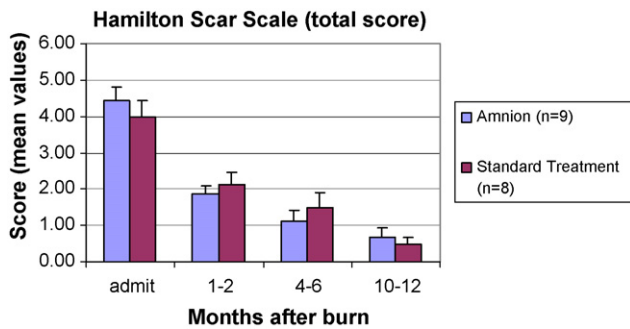


Fig. 2 – Hamilton Scar Scale long-term results. Results of photographic assessments using the Hamilton Scar Scale. No significant differences between long-term wound healing between amnion and standard treatment. Data presented as mean \pm S.E.M.

Trials have been performed in acute, partial and full-thickness wounds, and different forms of procurement and storage of amniotic membrane have been reported. Most of these studies, however, were performed *in vitro*, in pre-clinical animal studies, or in clinical trials that lacked adequate control groups and strict inclusion criteria. In the first large human trial with amniotic membrane, Gruss et al. [17] showed the benefit of amnion in decreasing wound bacterial counts, accelerating wound healing and promoting the growth of granulation tissue over chronic wounds and exposed bones in a cohort of 120 patients. The amniotic membranes used in this study were not separated from the chorion and only processed by repeatedly washing the material, with microbiology cultures used as proof of sterility of the membrane. The authors used amnion on ulcers, elective surgical wounds, infected and burn wounds. In a similar trial, Robson et al. [5] used amniotic membranes in 150 patients. While these trials from the 1970s certainly provided valuable data and first insights into the potential of amniotic membranes in wound healing, today's researchers in the United States face a much

higher threshold for clinical studies with human tissue allografts: exclusion of potential contamination with HIV, Hepatitis and Herpes viruses, highly regulated processing facilities, and strict procurement and storage rules imposed by the Food and Drug Administration and the American Association of Tissue Banks.

It has been shown in the literature, most recently by Adds et al. [18], that vaginally delivered amnion is more contaminated than amnion from cesarean sections. In our study, a production process of amniotic membranes was introduced that guarantees maximum safety and nearly eliminates the risk of viral and bacterial infection. In contrast to most of the previous studies, the conditions for initial amnion procurement were aseptic by only accepting donor tissues after cesarean sections; the membrane was then handled in sterile environments only and the quality of each single membrane was screened at various steps of the production process. This vigorous protocol accounted for the fact that, each year, less than 1% of the amniotic membranes produced by our tissue bank showed bacterial growth in the microbiological testing, and no infected material would ever be used. Various methods have been studied by other groups in order to sterilize the membranes and increase their efficacy in clinical use. Haberal et al. [11] used 0.5% silver nitrate for over 2 h; Robson and Krizek [4] used a rinse of 0.025% sodium hypochlorite solution to ensure sterility. Maral et al. [3] used glycerol-preserved amnion in a clinical trial with five patients and demonstrated excellent adherence, showed no allergic reaction, and had maximum patient comfort compared to standard dressings.

Taking into account the considerable amount of literature on amnion, there have been surprisingly few clinical trials to show the effects of amnion in burn wound healing. Our study is the first clinical trial with an exclusively pediatric burn population. The main objective of the study was therefore to document the use of amniotic membrane in a large cohort of patients with a uniform burn depth and location, and to show the safety and efficacy of this dressing type. Facial burns were chosen as a study object for numerous reasons: lack of good

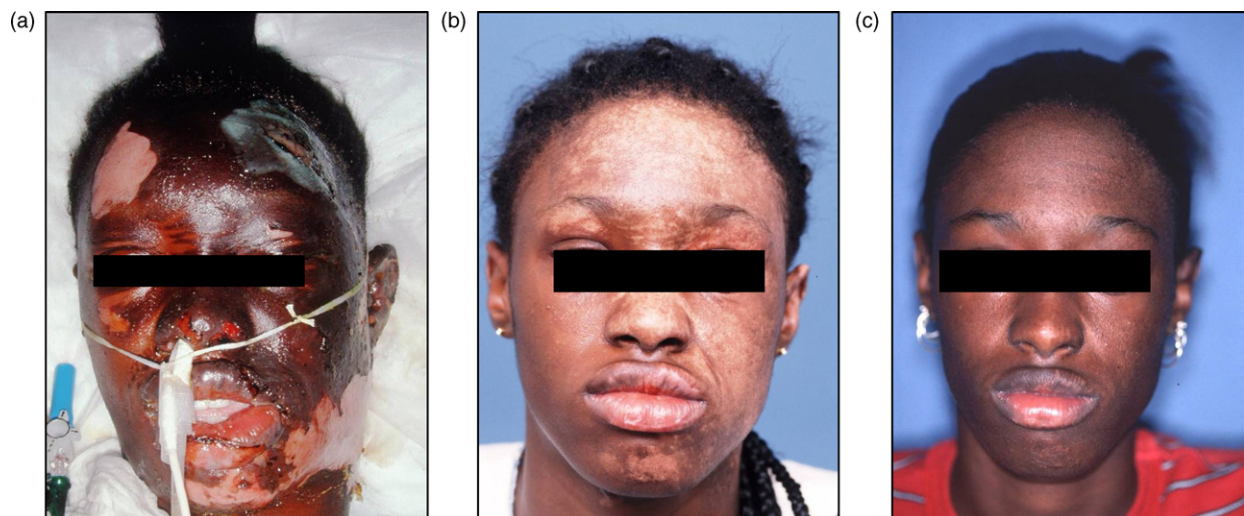


Fig. 3 – Long-term photographic results—Amnion. Fifteen-year-old female patient with partial-thickness facial burns after a house fire. Follow-up pictures over 1 year show complete healing and re-pigmentation.

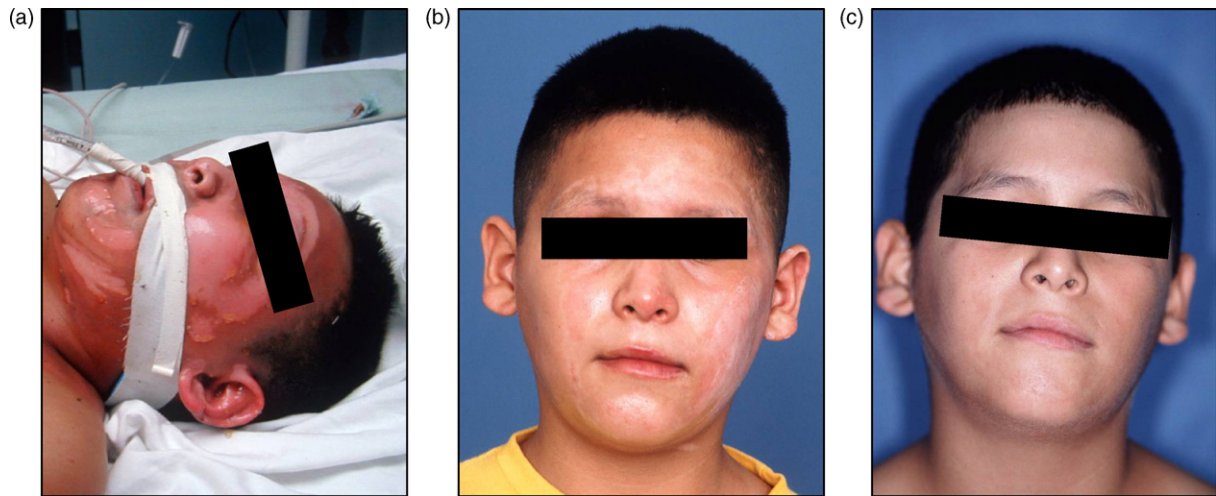


Fig. 4 – Long-term photographic results—Amnion. Eight-year-old male patient with partial-thickness facial burns after a scald injury. One year after the injury, no residuals of the burn can be observed.

treatment options for the face, high prevalence of facial burn injuries in the pediatric patient population (typically scald burns in younger children and flame burns from trash fires or explosives in adolescents), and the need for a highly adherent and moldable dressing type.

We excluded full-thickness or deep partial-thickness facial burns as well as burns over 40% TBSA and with full-thickness burns over 10% TBSA. Patients with these extensive burn injuries usually require longer ICU treatment and multiple visits to the operating theatre, which would obscure the outcome measurements of this study. However, we had to include patients who were moderately affected by burns to other parts of the body than the face, head and neck. A study with patients exclusively affected by facial burns would have been very desirable, especially in order to conduct a clean comparison with regard to pain reduction and patient comfort, but even in a highly specialized pediatric burn center like the Shriners Hospital for Children, an exclusive partial-thickness facial burn is a very rare event. Therefore, our primary outcomes were defined as the dressing change frequency in each group and the healing time, both in regards to the face.

We observed that in the amnion group, dressing changes and re-applications in the face were significantly less frequent than in the control group, with equal healing time and equal low rate of local reactions or infections. In a pediatric patient population, this presents a great advantage over the standard dressing methods. Pain reduction during dressing changes did not figure as a primary outcome of this study. In a donor site and burn wound healing study performed by Uhlig et al. [19], the wound healing capacity of a novel polymer dressing was examined. In the study design, pain was described as a primary endpoint and a visual pain analog scale was used for quantification. The patients, however, had only one type of treatment, and the patient population was exclusively adult. In our pediatric patient population, pain reduction after the application of amniotic membranes to the face could not be adequately measured

with the help of pain scales, due to the fact that most of the patients had painful second-degree injuries in other locations. Any measurement would have been compromised by the fact that patients were subject to dressing changes on other locations at the same time. Although only subjective, and based on personal experience of the authors and verbal communication with tubroom staff, it should be mentioned that during tubroom visits in the amnion group, with the membrane left in place and only the upper layer of the dressing removed, the overwhelming majority of the patients tolerated the procedure very well.

In the long-term outcome measurements, it became clear that amniotic membrane could not prevent hypertrophic scarring. Hypertrophy in burn scars usually develops between 2 and 6 months after burn; Bombaro et al. [20] reported a low incidence of hypertrophic scarring after burns, Deitch reported a twofold higher incidence in African-American than in Caucasian burn patients (30% versus 15%) [21]. Since then, there were no reports in the world literature on the prevalence of hypertrophic scarring in burns. From our study, we cannot draw a conclusion as to the prevalence of hypertrophic scarring in our patient population. Only a limited number of the patient population came back for long-term follow-up visits, and a high number was returning for treatment of their hypertrophic or elevated scars. In order to record the subtle differences between the grades of hypertrophic scarring and to exclude systematic errors like differences between ethnicities, a large number of patients would be required. We are, however, currently performing a large long-term outcome study in burned patients that is not only limited to facial burns, and which will shed more light on the prevalence of hypertrophic scarring and the factors that cause this condition.

The results of this study implicate that amniotic membranes can be used safely for temporary wound coverage. We did not observe a higher rate of infections than in the control group, achieved the same wound healing rate as with standard dressing regimens, and had to perform significantly less full

dressing changes in the amnion group. Looking at the wound healing in the long term, we did not see impaired cosmetic results after treatment with amnion.

Acknowledgements

This study was partly funded by The Clayton Foundation of Houston. We would like to acknowledge the clinic nursing staff of the Shriners Hospital for Children for their great support in conducting this study.

Human amniotic membrane is supplied by the tissue bank of the Shriners Hospital for Children.

Conflict of interest

None of the authors have commercial associations or financial relationships that might pose or create a conflict of interest with any information presented in the manuscript.

REFERENCES

- [1] Tyszkiewicz JT, Uhrynowska-Tyszkiewicz IA, Kaminski A, Dziedzic-Goclawska A. Amnion allografts prepared in the Central Tissue Bank in Warsaw. *Ann Transplant* 1999;4(3-4):85-90.
- [2] Sabella N. Use of fetal membranes in skin grafting. *Med Rec NY* 1913;83:478.
- [3] Maral T, Borman H, Arslan H, Demirhan B, Akinbingol G, Haberal M. Effectiveness of human amnion preserved long-term in glycerol as a temporary biological dressing. *Burns* 1999;25(7):625-35.
- [4] Robson MC, Krizek TJ. The effect of human amniotic membranes on the bacteria population of infected rat burns. *Ann Surg* 1973;177:144-9.
- [5] Robson MC, Krizek TJ, Koss N, Samburg JL. Amniotic membranes as a temporary wound dressing. *Surg Gynecol Obstet* 1973;136(6):904-6.
- [6] Ninman C, Shoemaker P. Human amniotic membranes for burns. *Am J Nurs* 1975;75:1468-9.
- [7] Salisbury RE, Carnes R, McCarthy LR. Comparison of the bacterial clearing effects of different biologic dressings on granulating wounds following thermal injury. *Plast Reconstr Surg* 1980;66:596-8.
- [8] Quinby Jr WC, Hoover HC, Schefflan M, Walters PT, Slavin SA, Bondoc CC. Clinical trials of amniotic membranes in burn wound care. *Plast Reconstr Surg* 1982;70(6):711-7.
- [9] Gajiwala K, Gajiwala AL. Evaluation of lyophilised, gamma-irradiated amnion as a biological dressing. *Cell Tissue Bank* 2004;5:73-80.
- [10] Douglas B. Homografts of fetal membranes as a covering for large wounds; especially those from burns; an experimental and clinical study. *J TN State Med Assoc* 1952;45:230-5.
- [11] Haberal M, Oner Z, Bayraktar U, Bilgin N. The use of silver nitrate-incorporated amniotic membrane as a temporary dressing. *Burns Incl Therm Inj* 1987;13(2):159-63.
- [12] Ramakrishnan KM, Jayaraman V. Management of partial-thickness burn wounds by amniotic membrane: a cost-effective treatment in developing countries. *Burns* 1997;23(Suppl 1):S33-6.
- [13] Ravishanker R, Bath AS, Roy R. Amnion Bank—the use of long term glycerol preserved amniotic membranes in the management of superficial and superficial partial thickness burns. *Burns* 2003;29:369-74.
- [14] Hennerbichler S, Reichl B, Pleiner D, Gabriel C., Eibl J., Redl H. The influence of various storage conditions on cell viability in amniotic membrane. *Cell Tissue Bank*, 2006.
- [15] Rennekampff HO, Rabbels J, Reinhard V, Becker ST, Schaller HE. Comparing the Vancouver Scar Scale with the cutometer in the assessment of donor site wounds treated with various dressings in a randomized trial. *J Burn Care Res* 2006;27(3):345-51.
- [16] Crowe JM, Simpson K, Johnson W, Allen J. Reliability of photographic analysis in determining change in scar appearance. *J Burn Care Rehabil* 1998;19(2):183-6.
- [17] Gruss JS, Jirsch DW. Human amniotic membrane: a versatile wound dressing. *Can Med Assoc J* 1978;118:1237-46.
- [18] Adds PJ, Hunt C, Hartley S. Bacterial contamination of amniotic membrane. *Br J Ophthalmol* 2001;85:228-30.
- [19] Uhlig C, Rapp M, Hartmann B, Hierlemann H., Planck H., Dittel K.K. Suprathel((R))—An innovative, resorbable skin substitute for the treatment of burn victims. *Burns* 2006.
- [20] Bombaro KM, Engrav LH, Carrougner GJ, Wiechman SA, Faucher L, Costa BA, et al. What is the prevalence of hypertrophic scarring following burns? *Burns* 2003;29(4):299-302.
- [21] Deitch EA, Wheelahan TM, Rose MP, Clothier J, Cotter J. Hypertrophic burn scars: analysis of variables. *J Trauma* 1983;23(10):895-8.